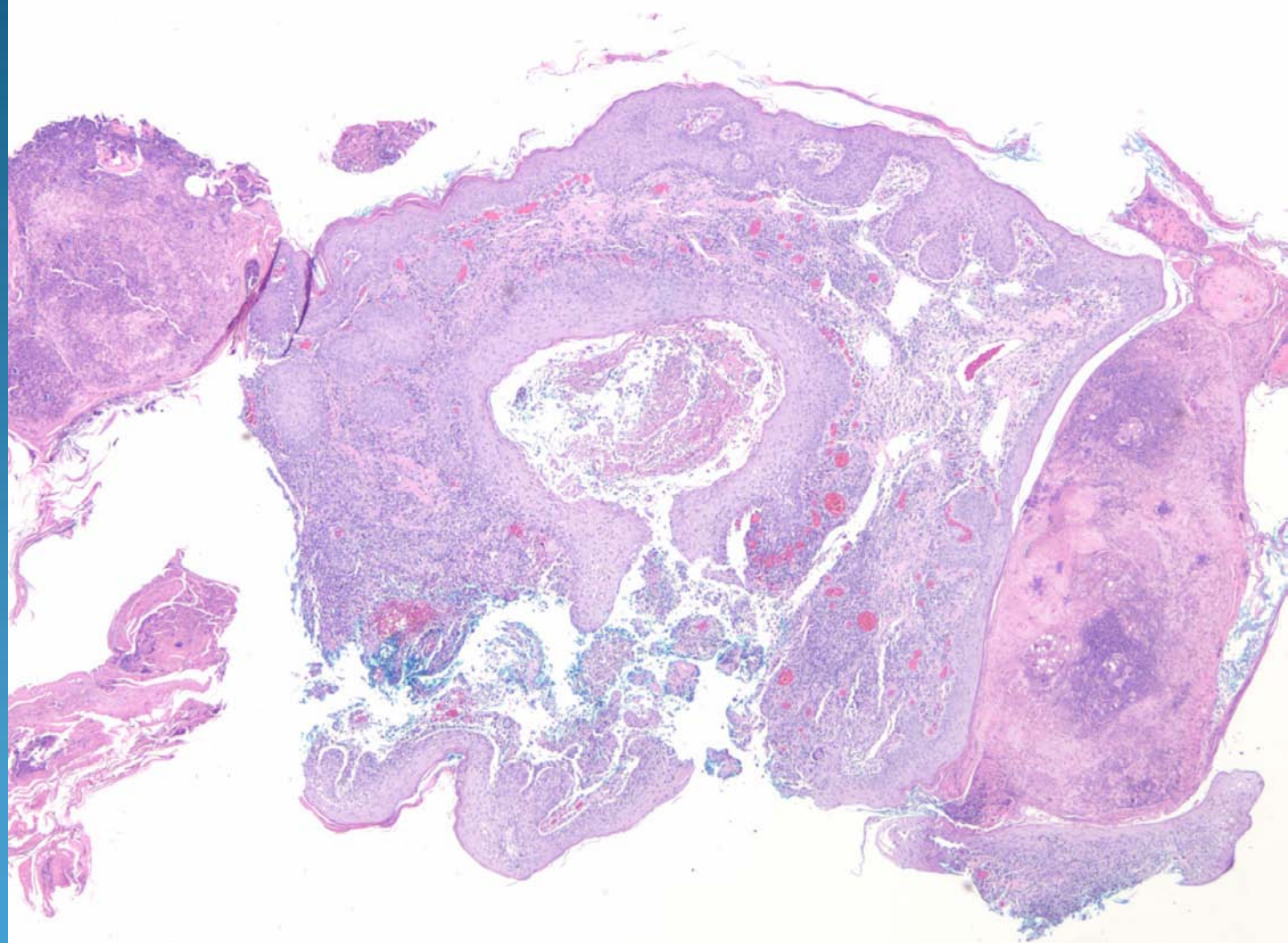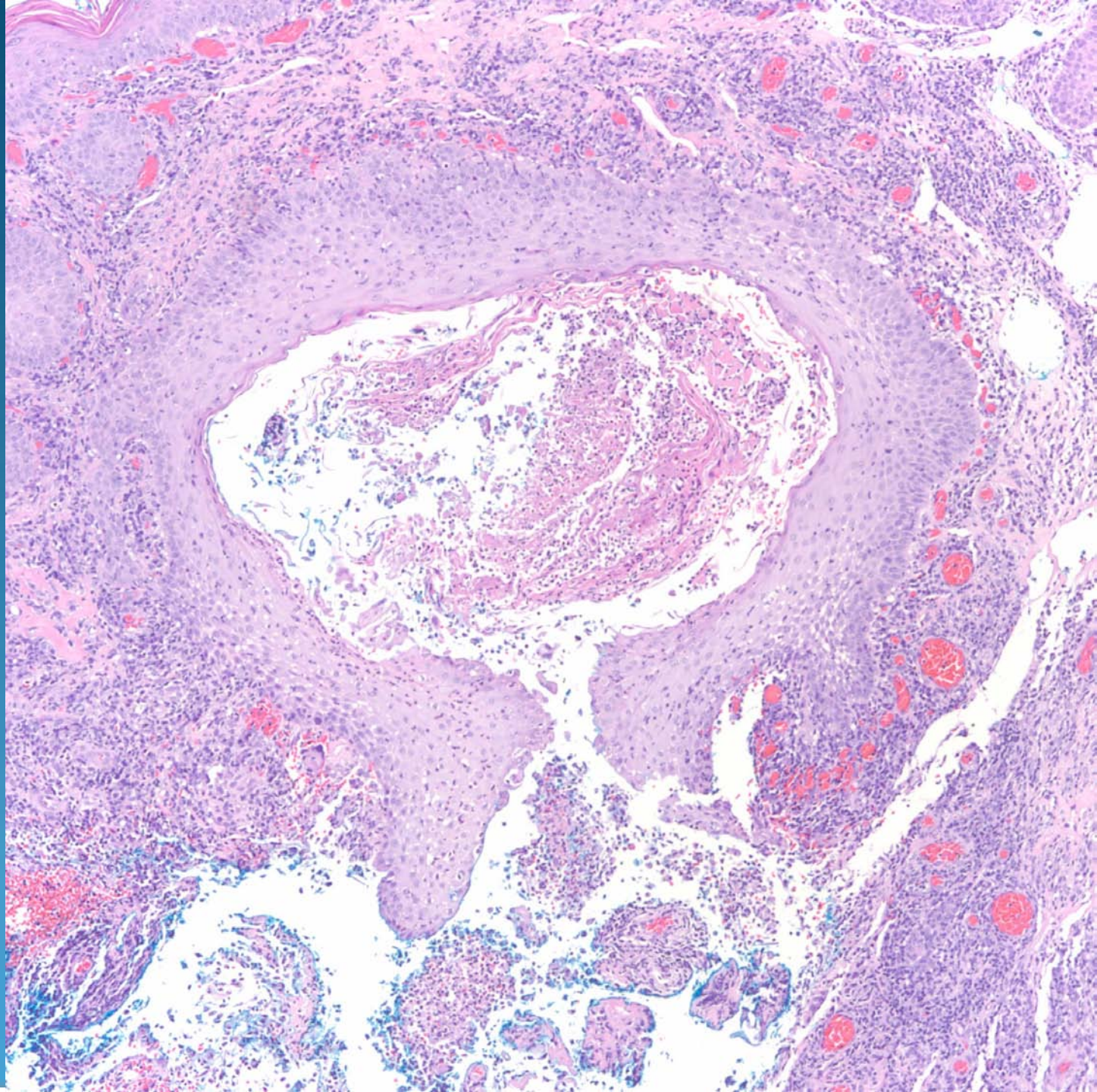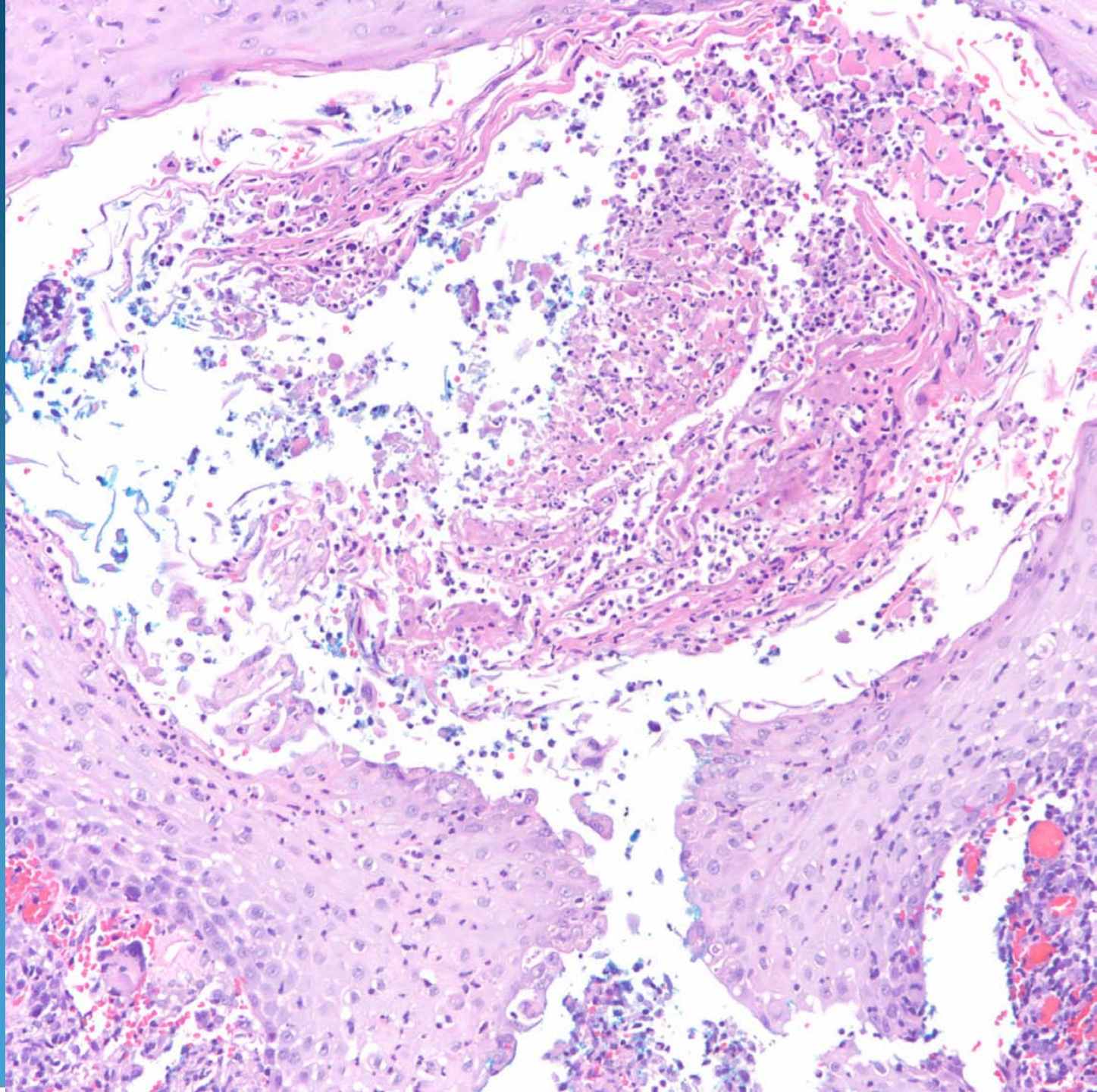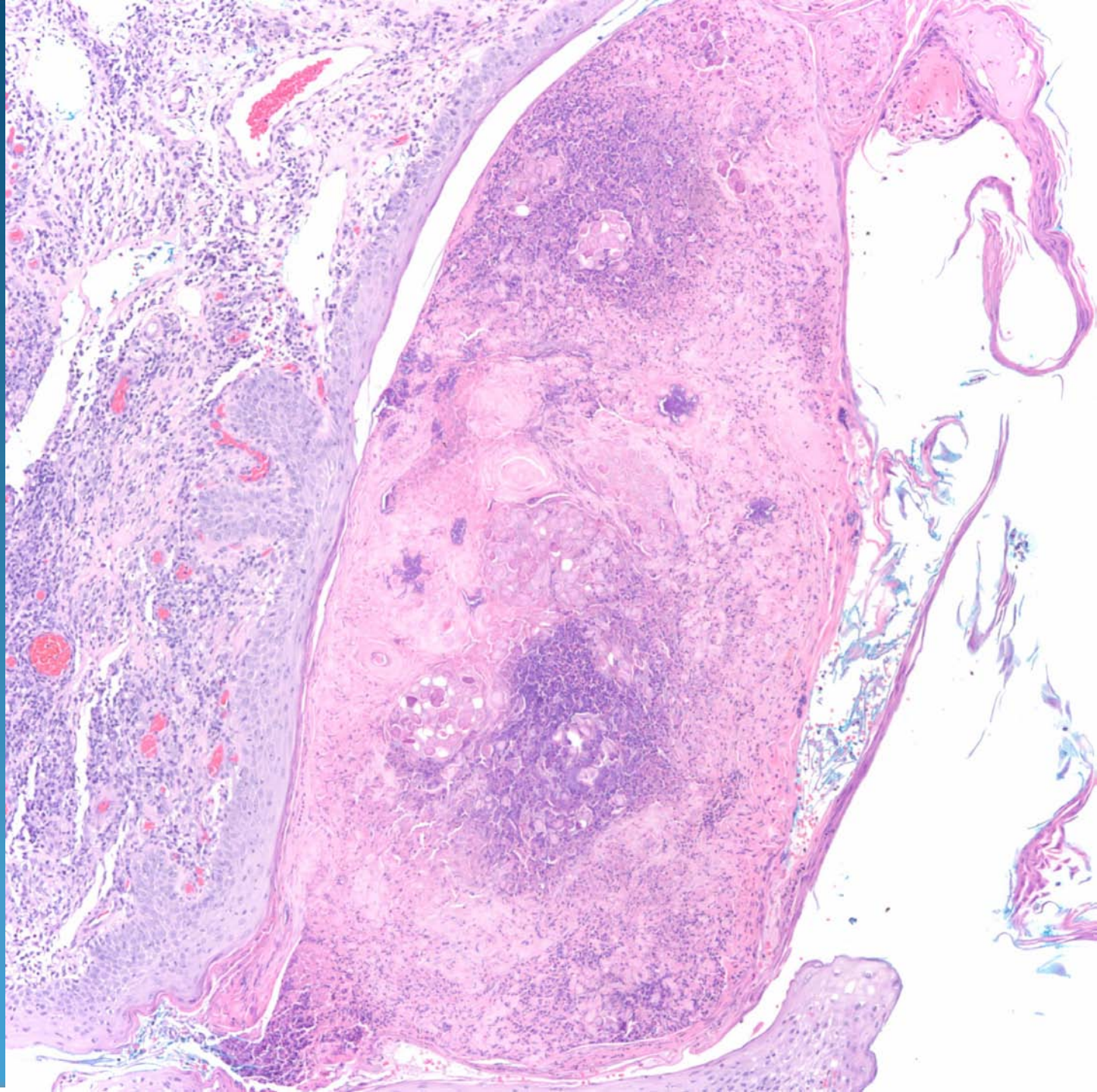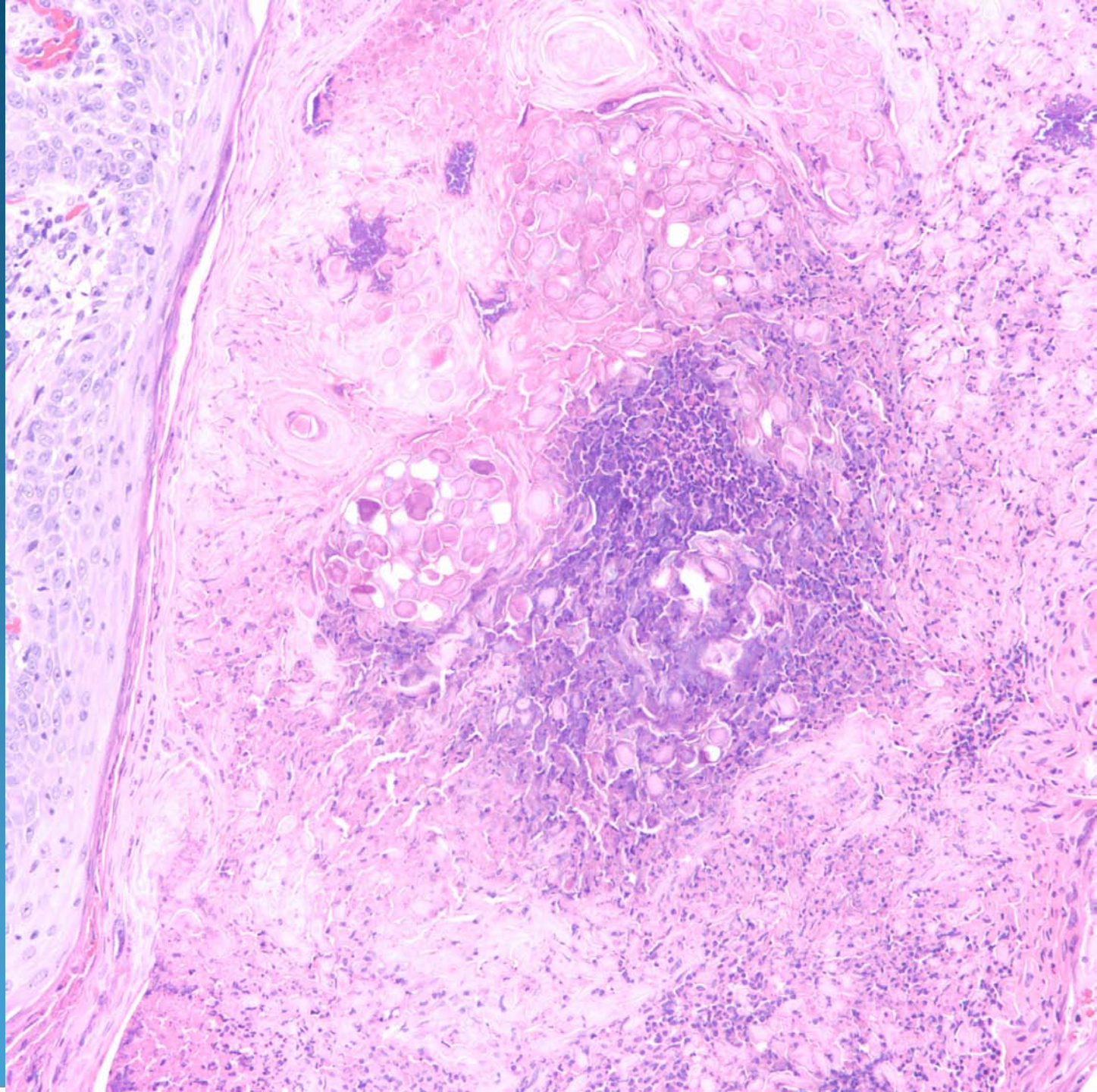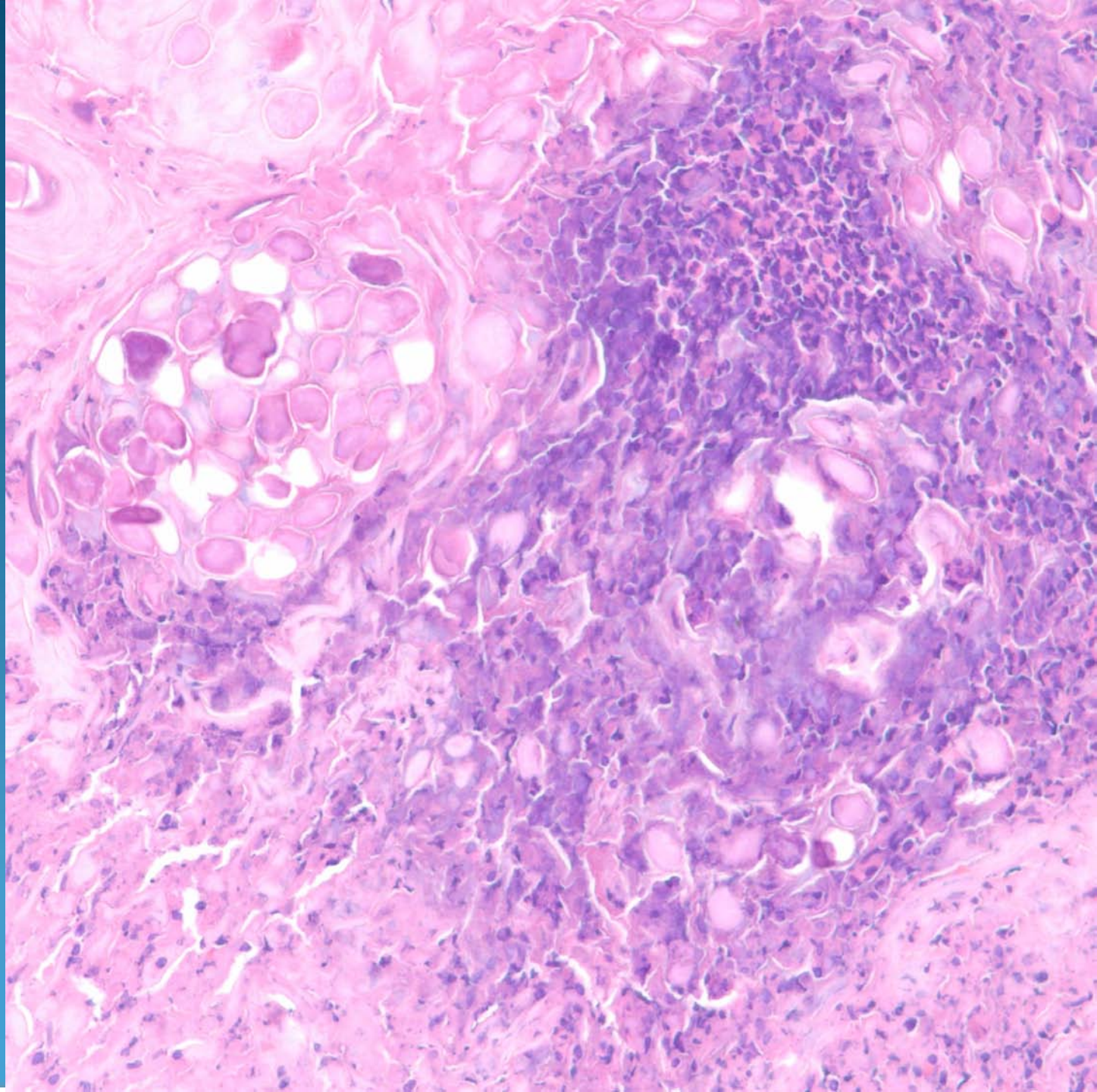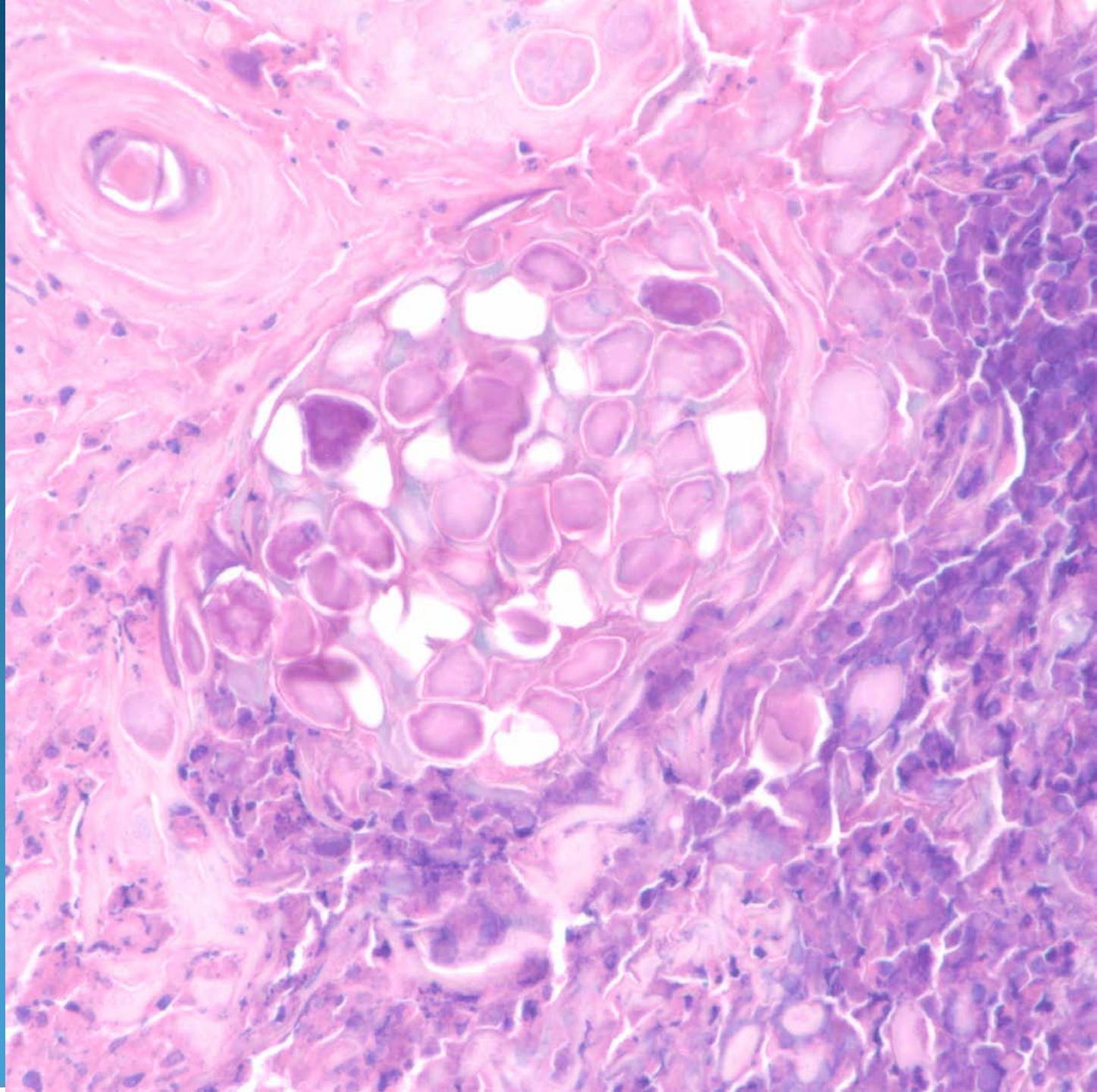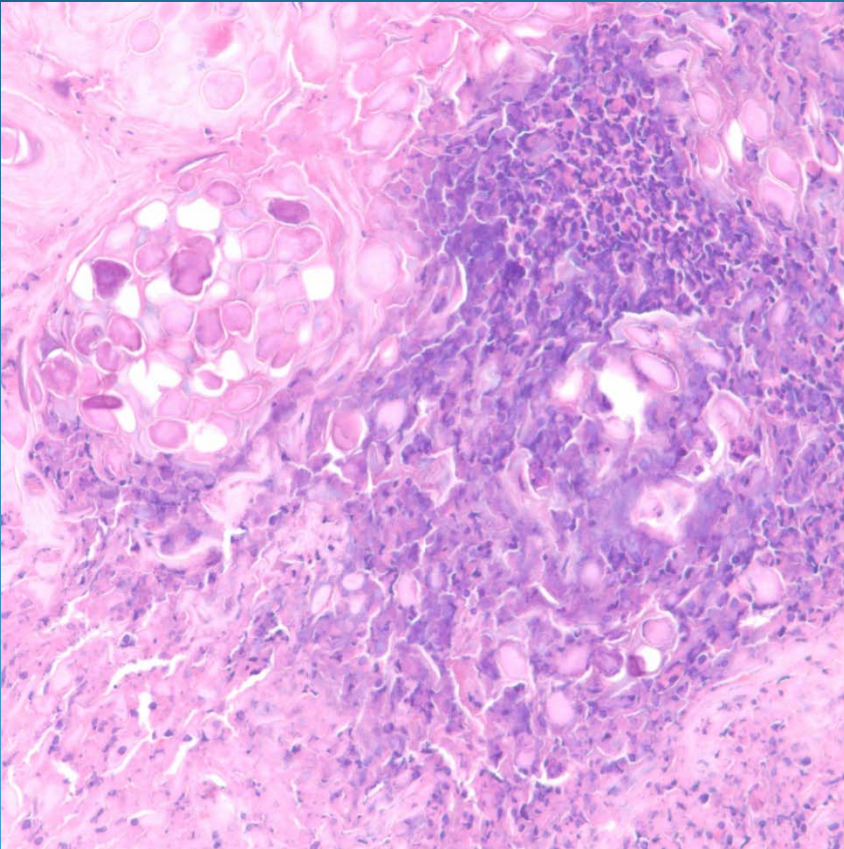


Molluscum contagiosum, inflamed
(with ruptured folliculitis)

Pearls



- Occasionally molluscum bodies (viral cytopathic changes) may be obscured by inflammation including granulomas or folliculitis
- Always examine hair follicles and inflammatory exudate, especially in a folliculitis in a younger person